

## Three cases of suspected pleuroparenchymal fibroelastosis after allogeneic hematopoietic cell transplantation

Shiori Morikawa, Nobuaki Fukushima, Tomoya Arakawa, Tomoki Fujii, Shuto Negishi, Yuma Kawamura, Miyo Goto, Kazutaka Ozeki, Akio Kohno

Department of Hematology and Oncology, Konan Kosei Hospital, Konan, Japan

### Abstract

This article reports the clinical course and imaging findings of three cases of suspected pleuroparenchymal fibroelastosis (PPFE) after allogeneic hematopoietic cell transplantation (HCT). All patients complained of dyspnea more than 5 years after HCT, had progressive restrictive deficits on respiratory function tests, and presented with pneumothorax, pleural thickening, or exacerbation of consolidation in the upper lobe of the lung. Though lung biopsy was not done in all three cases, the clinical findings and results of spirometry were compatible with those of PPFE. PPFE has been sporadically reported as a pulmonary complication of allogeneic HCT; however, clinical diagnostic criteria other than histological diagnosis and treatment methods have not yet been established. The accumulation of more cases is necessary to improve the prognosis of PPFE complications.

**Key words** pleuroparenchymal fibroelastosis, allogeneic hematopoietic cell transplantation

Submitted June 7, 2023; Accepted August 29, 2023; Published online October 27, 2023; Issued online November 25, 2023

Correspondence: Shiori Morikawa, Department of Hematology and Oncology, Konan Kosei Hospital, 137 Omatsubara, Takaya-cho, Konan, Aichi, 483-8704, Japan, E-mail: saltchoco3@gmail.com

### Introduction

Pulmonary complications that develop after allogeneic hematopoietic cell transplantation (HCT) occur in one-third of the patients and have high mortality rates<sup>1</sup>. Bronchiolitis obliterans and cryptogenic organizing pneumonia are known post-transplant pulmonary complications associated with autoimmunity and graft-versus-host disease (GVHD). Pleuroparenchymal fibroelastosis (PPFE) is a restrictive pulmonary disease that causes fibrosis of the pleura and adjacent pulmonary parenchyma, predominantly in the upper lobe. The term “PPFE” was first used by Frankel et al. in 2004<sup>2</sup>, and the idiopathic form is now listed as one of the rare idiopathic interstitial pneumonias in the classifications of the American Thoracic Society and the European Respiratory Society<sup>3</sup>. It progresses slowly but steadily, and the 5-year survival rate is < 30%, indicating a poor prognosis<sup>4</sup>. Recently, there have been sporadic reports on the development of PPFE after allogeneic HCT<sup>5</sup>; however, there are few comprehensive reports. The diagnosis is made based on characteristic imaging find-

ings and histopathology, and clinical diagnostic criteria have not yet been established.

We encountered three patients with clinically suspected PPFE following allogeneic HCT. Here, we describe the clinical aspects and outcomes of each case and discuss an effective index for clinical diagnosis and risk factors for developing PPFE after allogeneic HCT.

### Case Presentation

Patients' characteristics are listed in **Table 1**.

#### Case 1

A 44-year-old man was diagnosed with a blast crisis in chronic myelogenous leukemia and underwent cord blood transplantation (CBT) at 45 years of age in the second chronic phase with the conditioning regimen of fludarabine (25 mg/m<sup>2</sup>/day, 5 days), cyclophosphamide (CY) (50 mg/kg/day, 2 days), and 2 Gy of total body irradiation (TBI). Before undergoing CBT, multiple bullae were observed in the bilateral upper lobes of the lungs. Six months after the transplantation, the patient

**Table 1. Patient characteristics**

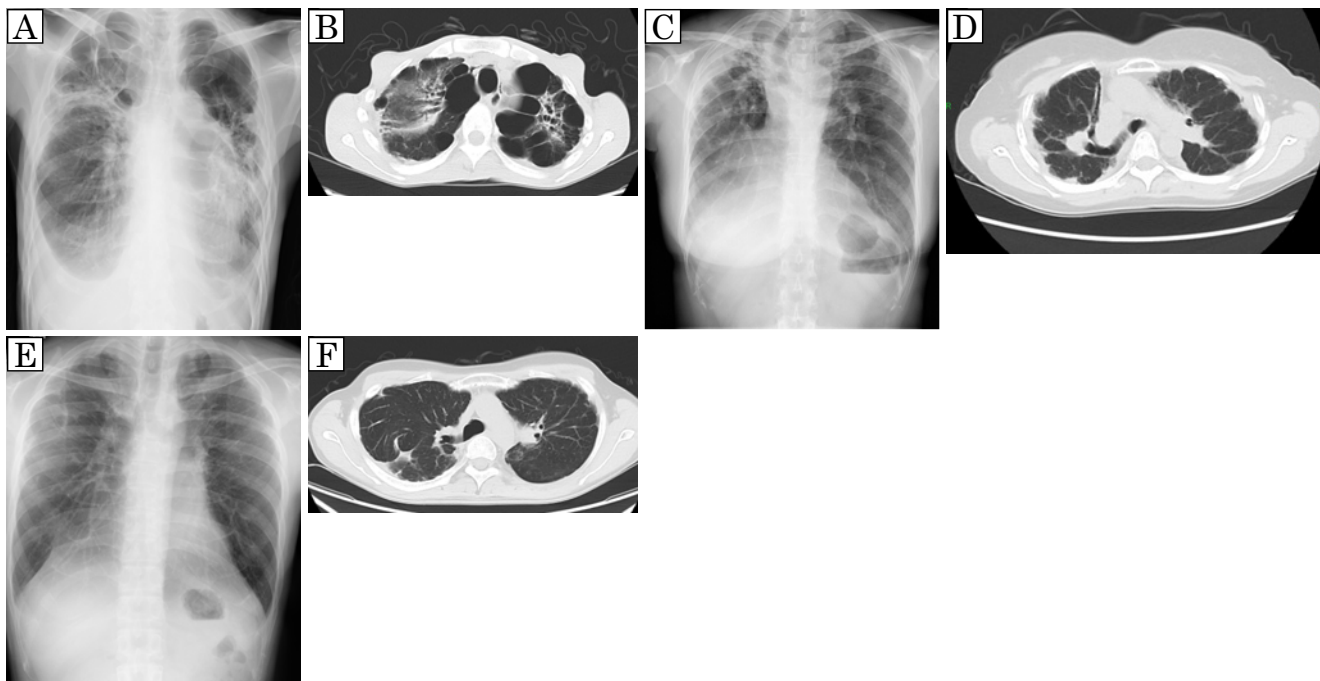
		Case 1	Case 2	Case 3	
Clinical presentation	Age/Sex	45/Male	36/Female	18/Male	
	BMI	12.0	19.2	18.8	
	Smoking history	N/A	20 cigarettes per day for 15 years	N/A	
	Underlying disease	CML	ENKL	T-LBL	
	Clinical stage at transplant	2nd CP	1st CR	2nd CR	
	Transplant type	CBT	CBT	Related PBSCT	
	Conditioning	Flu (25 mg/m <sup>2</sup> /day, 5 days), CY (50 mg/kg/day, 2 days), and TBI (2 Gy, 1 fraction)	CA (4 g/m <sup>2</sup> /day, 2 days), CY (60 mg/kg/day, 2 days), and TBI (12Gy, 4 fractions)	CY (60 mg/kg/day, 2 days), TBI (12 Gy, 4 fractions), and CSI (3 Gy, 1 fraction)	
	Time from HCT to diagnosis (month)	70	139	232	
	Symptoms	Dyspnea	Dyspnea on effort	Dyspnea on effort	
	Acute GVHD	Grade II	Grade I	None	
	Chronic GVHD	Skin	None	Progressive	None
		Other organs	None	None	None
	Immunosuppressant at onset	None	None	None	
	Spirometry	VC (L)	before HCT	3.4	3.0
in onset			1.3	1.5	2.9
latest			1.0	1.2	2.9
%VC (%)		before HCT	86.2	111.5	100.5
		in onset	35.0	58.3	70.1
		latest	26.1	49.0	69.7
FEV1 (L)		before HCT	2.7	2.4	4.4
		in onset	1.3	1.4	2.8
		latest	1.0	1.1	2.8
FEV1% (%)		before HCT	79.6	79.5	95.7
		in onset	96.2	92.9	99.3
		latest	98.0	86.6	98.6
%FEV1 (%)		before HCT	77.5	96.3	100.0
		in onset	39.5	66.8	74.9
		latest	30.6	52.6	75.3
RV/TLC (%)		before HCT	32.1	N/A	N/A
		in onset	57.1	46.6	42.0
		latest	63.7	51.0	44.4

BMI, body mass index; CML, chronic myeloid leukemia; ENKL, extranodal natural killer/T cell lymphoma, nasal type; T-LBL, T-lymphoblastic lymphoma; CP, chronic phase; CR, complete remission; CBT, cord blood transplantation; PBSCT, peripheral blood stem cell transplantation; Flu, fludarabine; CY, cyclophosphamide; TBI, total body irradiation; CA, cytarabine; CSI, craniospinal irradiation; HCT, hematopoietic cell transplantation; GVHD, graft versus host disease; VC, vital capacity; FEV1, forced expiratory volume in one second; RV, residual volume; TLC, total lung capacity

developed a pneumothorax and was treated with thoracic drainage. Six years after the transplantation, symptoms such as cough and dyspnea gradually worsened, and chest X-ray revealed worsening opacities in the upper lung fields. Computed tomography (CT) revealed emphysematous bullae clusters in both lung apices and consolidation in the left upper lobe (**Figure 1A and B**). His restrictive disorder had progressed (FEV1.0 1.0L, FEV1.0% 98.0%, %VC 26.1%, RV/TLC 63.7%). Seven years after the transplantation, the patient required home oxygen therapy.

## Case 2

A 35-year-old woman was diagnosed with extranodal NK/T-cell lymphoma that was suspected to be treatment-resistant. The patient underwent CBT at 36 years of age with the conditioning regimen of cytarabine (4 g/m<sup>2</sup>/day, 2 days), CY (60 mg/kg/day, 2 days), and 12 Gy of TBI. Five years after the transplantation, chest X-ray revealed suspected pleural thickening in the right apex, and CT showed bilateral pleural thickening and wedge-shaped consolidation (**Figure 1C and D**). Eleven years after the transplantation, she had a slow decline in respiratory function (FEV1.0 1.1L, FEV1.0% 86.6%, %VC 49.0%, RV/TLC 51.0%), but no demand



**Figure 1. Chest X-ray and computed tomography (CT) findings of each case**

(A), (C), and (E) show X-ray images of cases 1, 2, and 3, respectively. (B), (D), and (F) show CT images of cases 1, 2, and 3, respectively. Chest X-ray and CT show bilateral superior lobe pleural thickening and multiple subpleural consolidations.

for oxygen.

### Case 3

An 18-year-old man in second remission of T-lymphoblastic lymphoma underwent allogeneic peripheral blood stem cell transplantation from an HLA-matched sibling donor with the conditioning regimen of CY (60 mg/kg/day, 2 days), 12 Gy of TBI, and 3 Gy of craniospinal irradiation. Nine years after the transplantation, dyspnea on exertion and restrictive disability progressed. Chest X-ray revealed mild pleural thickening at the apex of the lung, and CT showed wedge-shaped consolidation just below the pleura of both the upper lobes and flattening of the thorax (**Figure 1E and F**). Although gradual progression of restrictive disability was observed (FEV1.0 2.8L, FEV1.0% 98.6%, %VC 69.7%, RV/TLC 44.4%), periodic respiratory function tests and follow-up were performed.

### Discussion

Advances in allogeneic HCT technology and an increase in long-term survivors have led to previously unknown late pulmonary complications after allogeneic HCT, the progression of which affects the quality of life of long-term survivors after allogeneic HCT. Therefore, accurate diagnosis and timely therapeutic intervention are desired. PPFE after allogeneic HCT has gained increasing recognition in recent years after a case report

first published in 2011<sup>6</sup>. The diagnosis is made based on radiographic imaging findings, including consolidation predominantly in the upper lung field and volume reduction in the upper lobe, and pathological findings, including fibrosis with poor inflammatory cell infiltration in the alveolar septum just below the pleura. Though there are many cases where it is difficult to perform a lung biopsy depending on the patient's medical condition, the international clinical diagnostic criteria that do not require a surgical lung biopsy have not yet been established. Watanabe *et al.* set RV/TLC %predicted > 80-115% (depending on the physical state) as one of the diagnostic criteria for idiopathic PPFE without surgical lung biopsy in 2019. They also emphasized low body mass index and a flattened chest cage as clinical findings for suspicion of PPFE<sup>7</sup>. Surgical lung biopsy was not available in our three cases, and the diagnosis of PPFE was not confirmed. However, clinical symptoms, pulmonary function tests, and radiological findings were suspicious of PPFE. High levels of RV/TLC %predicted and an increased RV/TLC ratio are also functional characteristics of idiopathic PPFE<sup>8</sup>. The RV/TLC ratio tended to increase annually in all three cases (**Supplementary figure/table**). RV/TLC ratio, which does not require invasive procedures, is considered useful clinical laboratory findings for the diagnosis of secondary PPFE because RV/TLC ratio does not theoretically increase in restrictive lung injury due to extrapulmonary diseases such as skin

sclerosis in chronic GVHD.

The risk of developing PPFE after transplantation is thought to be associated with the use of alkylating agents, irradiation, and respiratory infections; however, since these conditions can equally affect many allograft patients who have not had PPFE, they are not PPFE-specific<sup>5</sup>. The development of PPFE may be more complicated by the patients' backgrounds or other factors under transplant-related conditions. Therefore, we suggest that continuous pulmonary function testing may be important for all patients.

No drugs have been confirmed to prevent the progression of PPFE, and corticosteroids, immunosuppressive drugs, and antifibrotic agents have been used in some cases, with poor efficacy<sup>5, 9, 10</sup>. Since the symptoms progress slowly, the patients are often observed without treatment. Lung transplantation is the most effective treatment<sup>5, 9</sup> but not an easy treatment approach. We did not administer any drugs to our three cases, and none of them received lung transplantation.

One of the reasons why the development of treatment methods for PPFE has not progressed is that the number of cases is small and it is difficult to organize clinical trials to verify therapeutic effects. Based on this experience, it is necessary to first establish diagnostic criteria that do not require histopathological diagnosis and to accumulate cases in the future to improve the prognosis of PPFE after HCT.

### Author Contributions

SM collected and interpreted the data and wrote the manuscript. AK treated the patients. TA, TF, SN, YK, MG, NF, KO, and AK supervised the writing of the manuscript. All authors participated in the interpretation of the results and approved the final manuscript.

### Informed Consent

Informed consent was obtained by all participants in this study.

### Conflicts of Interest

The authors declare no conflict of interest. Disclosure

forms provided by the authors are available on the website.

### References

- Haider S, Durairajan N, Soubani AO. Noninfectious pulmonary complications of haematopoietic stem cell transplantation. *Eur Respir Rev.* 2020; **29**: 190119.
- Frankel SK, Cool CD, Lynch DA, Brown KK. Idiopathic pleuroparenchymal fibroelastosis: description of a novel clinicopathologic entity. *Chest.* 2004; **126**: 2007-13.
- Travis WD, Costabel U, Hansell DM, King TE, Jr., Lynch DA, Nicholson AG, et al. An official American Thoracic Society/European Respiratory Society statement: Update of the international multidisciplinary classification of the idiopathic interstitial pneumonias. *Am J Respir Crit Care Med.* 2013; **188**: 733-48.
- Enomoto Y, Nakamura Y, Satake Y, Sumikawa H, Johkoh T, Colby TV, et al. Clinical diagnosis of idiopathic pleuroparenchymal fibroelastosis: A retrospective multicenter study. *Respir Med.* 2017; **133**: 1-5.
- Arndt P. Pleuroparenchymal Fibroelastosis: A Review with a Focus on a Non-Infectious Complications after Hematopoietic Stem Cell Transplant. *Biomedicine.* 2023; **11**: 924.
- von der Thusen JH, Hansell DM, Tominaga M, Veys PA, Ashworth MT, Owens CM, et al. Pleuroparenchymal fibroelastosis in patients with pulmonary disease secondary to bone marrow transplantation. *Mod Pathol.* 2011; **24**: 1633-9.
- Watanabe K, Ishii H, Kiyomi F, Terasaki Y, Hebisawa A, Kawabata Y, et al. Criteria for the diagnosis of idiopathic pleuroparenchymal fibroelastosis: A proposal. *Respir Investig.* 2019; **57**: 312-20.
- Ishii H, Kinoshita Y, Kushima H, Nagata N, Watanabe K. The similarities and differences between pleuroparenchymal fibroelastosis and idiopathic pulmonary fibrosis. *Chron Respir Dis.* 2019; **16**: 1479973119867945.
- Chua F, Desai SR, Nicholson AG, Devaraj A, Renzoni E, Rice A, et al. Pleuroparenchymal Fibroelastosis. A Review of Clinical, Radiological, and Pathological Characteristics. *Ann Am Thorac Soc.* 2019; **16**: 1351-9.
- Bondeelle L, Gras J, Michonneau D, Houdouin V, Hermet E, Blin N, et al. Pleuroparenchymal fibroelastosis after allogeneic hematopoietic stem cell transplantation. *Bone Marrow Transplant.* 2020; **55**: 982-6.

<https://doi.org/10.31547/bct-2023-018>

Copyright ©2023 Asia-Pacific Blood and Marrow Transplantation Group (APBMT). This is an open access article distributed under CC BY-NC license (<https://creativecommons.org/licenses/by-nc/4.0/>).